Immunotherapy of myositis: issues, concerns and future prospects

Marinos C. Dalakas

Abstract | The main inflammatory myopathies within the myositis group include polymyositis, dermatomyositis and inclusion-body myositis (IBM). Although potentially treatable, various practical issues have an impact on the response of these conditions to therapy. The most common reason for therapeutic failure is that the treatment targets the wrong disease, often owing to poor distinction of polymyositis from difficult-to-treat mimics such as sporadic IBM, necrotizing myopathies and inflammatory dystrophies. Evidence from uncontrolled studies suggests that polymyositis and dermatomyositis respond to treatment with prednisone at least to some degree. Empirically, adding an immunosuppressive drug might offer a 'steroid-sparing' effect or perhaps additional benefit. Intravenous immunoglobulin is proven effective as a second-line agent in patients with dermatomyositis and also seems to be effective for those with polymyositis, but offers only minimal and transient benefit to a small proportion of patients with IBM. Small, uncontrolled series suggest other agents such as rituximab or tacrolimus might offer some benefit in disease refractory to the aforementioned therapies, although IBM is resistant to most therapies. Novel agents are emerging as potential treatment options for all forms of myositis. This Review highlights common pitfalls in therapy, discusses emerging new therapies, and provides a practical therapeutic algorithm.

Dalakas, M. C. *Nat. Rev. Rheumatol.* advance online publication 2 February 2010; doi:10.1038/nrrheum.2010.2

MedscapeCME Continuing Medical Education online

This activity has been planned and implemented in accordance with the Essential Areas and policies of the Accreditation Council for Continuing Medical Education through the joint sponsorship of MedscapeCME and Nature Publishing Group.

MedscapeCME is accredited by the Accreditation Council for Continuing Medical Education (ACCME) to provide continuing medical education for physicians.

MedscapeCME designates this educational activity for a maximum of 0.75 **AMA PRA Category 1 Credits™**. Physicians should only claim credit commensurate with the extent of their participation in the activity. All other clinicians completing this activity will be issued a certificate of participation. To participate in this journal CME activity: (1) review the learning objectives and author disclosures; (2) study the education content; (3) take the post-test and/or complete the evaluation at **http://www.medscapecme.com/journal/nrrheum**; and (4) view/print certificate.

Learning objectives

Upon completion of this activity, participants should be able to:

1. Distinguish clinical characteristics of different types of myositis.
2. Diagnose different types of myositis effectively.
3. Identify accepted first-line therapy for polymyositis and dermatomyositis.
4. Treat patients who fail primary therapy for polymyositis and dermatomyositis.

Competing interests
The author declares associations with the following companies: Baxter Healthcare, Octapharma and Talecris Biotherapeutics. See the article online for full details of the relationships. The Journal Editor J. Buckland and the CME question author C. P. Vega declare no competing interests.

Introduction

Myositis is a generic term used to describe a group of acquired inflammatory myopathies that represent a potentially treatable category of autoimmune muscle disorders. The most common subtypes of myositis include polymyositis, dermatomyositis and inclusion-body myositis (IBM). Features common to all of these subtypes include moderate-to-severe muscle weakness, endomysial inflammation and elevated levels of creatine kinase, but each subset also has unique clinical, immunopathologic and histologic criteria.[1–5] Identification of the correct subtype is fundamental to successful disease management because each has a different prognosis and response to therapy. This Review identifies common errors in clinical and histological diagnosis and provides practical guidelines on current therapies. Progress in immunotherapy for polymyositis and dermatomyositis is discussed and new agents are identified. The complex nature of IBM, where inflammation and autoimmunity against muscle fibers coexists with features of degeneration, is also summarized and the latest therapies for this disorder are presented.

Diagnosis of myositis subtypes

Dermatomyositis affects patients of all ages and presents with subacute onset of skin changes that accompany or precede proximal muscle weakness, which occurs in a symmetrical pattern and can vary in degree from mild to severe. Typical skin manifestations include a heliotrope rash on the upper eyelids, face, knees, elbows, neck, anterior chest, back or shoulders, and erythema of the knuckles with a raised, violaceous, scaly eruption (known

Imperial College London, Burlington Danes Building, Hammersmith Hospital Campus, Office E517, Du Cane Road, London W12 0NN, UK.
m.dalakas@imperial.ac.uk

© 2010 Macmillan Publishers Limited. All rights reserved

Key points

- Correct diagnosis of myositis subtype and monitoring of response to therapy with objective means that document changes in muscle strength are integral to the effective treatment of myositis
- Immunotherapy for polymyositis and dermatomyositis primarily involves corticosteroids and might incorporate the addition of other immunosuppressive agents
- Intravenous immunoglobulin might be effective in patients with disease refractory to first-line immunotherapy
- Inclusion-body myositis has a complex disease mechanism and can be difficult to treat with conventional immunotherapy
- Various factors in the immunopathogenesis of myositis represent targets for future therapeutic interventions

as Gottron rash).[1–5] Myalgia can occur early in the disease course, especially when dermatomyositis occurs in the setting of a connective tissue disorder; however, when muscle pain is severe, involvement of the fascia should be suspected. An underlying malignancy might be present in up to 15% of cases of adult dermatomyositis;[6] for this reason a thorough work-up and careful monitoring for cancer is necessary, especially in the first 3 years after onset of dermatomyositis.

In contrast to dermatomyositis, which is easily identifiable by the presence of skin lesions, polymyositis has no unique clinical features and remains a diagnosis of exclusion. Polymyositis is an acquired myopathy that affects proximal muscles symmetrically and occurs subacutely (over a period of weeks to months) in adults who do not have a rash, a positive family history of a neuromuscular disease, previous exposure to myotoxic drugs, or clinical signs of IBM as described below. As a stand-alone entity, polymyositis is a rare disorder. Although myalgia can occur early in the disease, in patients with severe muscle pain who give the impression of reduced strength owing to suboptimal effort (a 'give-away' pattern of weakness), fasciitis or fibromyalgia should be suspected despite the presence of transient, mild elevations in creatine kinase levels.

IBM has an insidious onset, over a period of years, and a slow progression. It affects both proximal and distal muscles, and results in substantial weakness and atrophy. Facial and pharyngeal muscles are often affected, resulting in episodes of choking.[1,7,8] IBM is usually suspected when a patient with presumed polymyositis does not respond to steroid therapy, but a potential clue to early diagnosis of IBM is involvement of distal muscles—especially foot extensors and deep finger flexors—almost from the outset.[1,3,7–10] Weakness and atrophy can be asymmetric, with selective involvement of the quadriceps, iliopsoas, triceps, biceps, and forearm flexor muscles. Axial muscles can also be affected, which can result in camptocormia or head-drop.

Diagnosis of the exact myositis subtype is based on the combination of clinical history, the rate of disease progression, the pattern of muscle involvement, levels of serum muscle enzymes, and results of electromyography and muscle biopsy investigations. Serum muscle enzymes—mainly creatine kinase and aldolase, but also serum glutamic oxaloacetic transaminase and serum glutamic pyruvic transaminase—are generally elevated in all myositis subtypes but they can occur at normal, or only slightly elevated, levels in some cases of dermatomyositis and IBM. Electromyography can reveal myopathic features, characterized by increased spontaneous activity and myopathic units on voluntary activation, in all subtypes and to a varying degree, and is mainly useful for the exclusion of neurogenic disorders. However, electromyography is insufficiently sensitive to differentiate an inflammatory myopathy from toxic or dystrophic myopathies. Muscle biopsy reveals the distinct inflammatory features of each subtype and, in spite of some limitations—attributable to disease heterogeneity and variability in the typical pathologic findings between biopsy sites—biopsy remains the most sensitive and specific diagnostic tool in cases of myositis. In dermatomyositis, inflammation is perivascular or at the periphery of the fascicle and is often associated with perifascicular atrophy; in polymyositis and IBM, inflammation occurs in multiple foci within the endomysial parenchyma and consists predominantly of $CD8^+$ T cells that invade non-necrotic muscle fibers that express the MHC-I antigen. The CD8–MHC complex is characteristic and useful for the diagnosis because it helps distinguish polymyositis and IBM from inflammatory dystrophies and necrotizing myositis.[1,4,5] Plasma cells and dendritic cells are frequent among the infiltrates in polymyositis, dermatomyositis and IBM.[11] IBM is histologically distinct from polymyositis and dermatomyositis because of the presence of rimmed vacuoles that contain tubulofilaments 12–16 nm long, Congo-red-positive amyloid deposits and cytochrome oxidase (COX)-negative fibers.[12–14]

Pitfalls in diagnosis and therapy

Errors in the diagnosis of myositis subtypes can lead to the initiation of unnecessary therapies, or delays in initiating the correct therapy. The most common cause of clinical misdiagnosis is erroneous interpretation of the muscle biopsy. The majority of patients labeled as having 'polymyositis unresponsive to therapy' often have IBM, necrotizing myopathy, or an adult-onset inflammatory dystrophy, such as those arising from mutations in dysferlin, caveolin, dystrophin or calpain (Box 1). Several common pitfalls lead to erroneous interpretation of muscle biopsy results, which arise from a failure to appreciate the significance of key facts. First, perifascicular atrophy is a sign characteristic of dermatomyositis, even in the absence of infiltrates, and can be helpful to diagnose those patients with dermatomyositis who present without overt skin changes. Second, muscle fiber necrosis, when predominantly associated with macrophages and sparse lymphocytes, is almost always seen in necrotizing myositis, toxic myopathies and dystrophies,[15,16] but rarely occurs in polymyositis and IBM, where muscle fiber invasion and necrosis is always mediated by lymphocytes. Third, ubiquitous expression of MHC-I antigen is a sign characteristic of polymyositis and IBM,[17,18] but not of inflammatory dystrophies, where MHC- I expression is not ubiquitous but limited to regenerating fibers or to a

© 2010 Macmillan Publishers Limited. All rights reserved

few fibers invaded by lymphoid cells. Fourth, in up to 15% of patients who present with the typical IBM phenotype, biopsy shows only inflammation without vacuoles;[19] such patients have 'probable IBM' or 'clinical IBM'. In these cases, the presence of COX-negative fibers[20] and signs of chronicity should lead to the suspicion of IBM and the performance of a repeat muscle biopsy.

A tactical error in therapy is the practice of 'chasing' changes in creatine kinase level as a sole sign of response to therapy or of an impending relapse. Although improvements in the patient's strength occur in concert with falls in serum levels of creatine kinase, the reverse is not always true. Many clinically ineffective immunotherapies, such as plasmapheresis, result in a decrease in levels of serum muscle enzymes.[21,22] Unfortunately, this serological change is interpreted as a sign of improvement, especially if it is associated with a subjective sense of feeling better, as communicated by the patient and inferred by the clinician, but not necessarily with an increase in strength and activities of daily living. Serum creatine kinase level is helpful as an auxiliary measure of treatment response but should not be relied on as the sole marker that defines response. The main goals of therapy remain the objective demonstration of increased strength, as well as improvements in performance of activities of daily living and in systemic manifestations.

Box 1 | Disorders commonly misdiagnosed as polymyositis

- Inclusion-body myositis
- Inflammatory, sporadic limb-girdle muscular dystrophy (such as dysferlinopathy, calpainopathy, caveolinopathy, or sarcoglycanopathy)
- Metabolic myopathy (such as phosphorylase deficiency or acid maltase deficiency)
- Drug-induced myopathies with some secondary inflammatory features (such as myopathy attributable to use of statins or antimalaria drugs in patients with rheumatoid arthritis)
- Acute necrotizing myopathy
- Atypical, adult-onset mitochondrial myopathies, without ophthalmoplegias
- Fasciitis and fibromyalgia (especially in patients with pain who have transient but mild elevation of serum creatine kinase level)

Immune targets for myositis therapy

The cause of polymyositis, dermatomyositis and IBM is unknown, but an autoimmune pathogenesis is strongly implicated.

In dermatomyositis, early activation of the complement cascade leads to the formation and deposition of membranolytic attack complex on the endomysial capillaries, which leads to their destruction.[1–5,23–25] Activation of B cells and plasmacytoid dendritic cells is prominent in the perimysial and perivascular regions.[2,11,26] Upregulation of chemokines, adhesion molecules and their receptors on the endothelial cell wall facilitates transmigration of lymphoid cells to the endomysial and perimysial spaces.[27–31] Various molecules, such as interferon-inducible proteins including MxA and signal transducer and activator of transcription (STAT)-1, cathepsins, cytokines such as transforming growth factor β, cytokine-related signal transduction molecules, and MHC class I, as well as regeneration and stressor molecules such as neural cell adhesion molecule (NCAM) and αβ-crystallin, are prominently expressed in the perifascicular regions, but their pathogenic significance remains unclear.[25,32]

In polymyositis and IBM, $CD8^+$ cytotoxic T cells clonally expand *in situ,* form immunological synapses with the healthy muscle fibers they invade, and lead to muscle fiber necrosis via the perforin pathway.[33–35] This concept is supported by the observed rearrangement of T-cell-receptor genes among autoinvasive T cells, and the expression of co-stimulatory molecules, adhesion molecules and cytokines.[36–42] Certain cytokines, such as interferon-γ, interleukin (IL)-1β and tumor necrosis factor (TNF), exert a stimulatory effect on the muscle fibers to secrete cytokines in an auto-amplificatory process that perpetuates inflammation (Figure 1).[43]

Autoantibodies against cytoplasmic ribonucleoproteins involved in translation and protein synthesis are found in up to 20% of patients with myositis and could be markers of specific phenotypes, but their pathogenic role remains elusive. The anti-Jo-1 autoantibody, which is directed against histidyl-transfer RNA synthetase, is associated with interstitial lung disease and its presence should prompt investigations into lung involvement.[44]

Accordingly, as shown in Figure 1, the following cells and molecules are the most specific targets for therapeutic interventions in polymyositis, dermatomyositis and IBM: cytokines and chemokines, molecules in the synapse between T cells and muscle, T cells and T-cell-activation factors, B cells, and T-cell and B-cell transmigration molecules.[45] In the case of dermatomyositis, complement is also a therapeutic target, but this is not depicted in Figure 1.

Polymyositis and dermatomyositis therapy

Limitations of current immunotherapies

The main concern with the treatment of myositis is a lack of controlled trials and the absence of standardized outcome measures to capture clinically meaningful changes that correlate with disability and quality of life. As a result, the choice of treatment or the sequence in which various immunotherapeutic drugs are used is not evidence-based but rather is empirical and often influenced by physician experience, prejudice and personal conception of the efficacy:safety ratio of a given therapy.

First-line therapy

Prednisone is arguably the first-line drug for the treatment of polymyositis and dermatomyositis, although this is based on experience rather than evidence from controlled trials. The general preference is to start with high-dose prednisone, at least 1 mg/kg or 60–80 mg per day, administered as a single daily morning dose (after breakfast).[46] After 3–4 weeks, the daily dose is slowly reduced or

© 2010 Macmillan Publishers Limited. All rights reserved

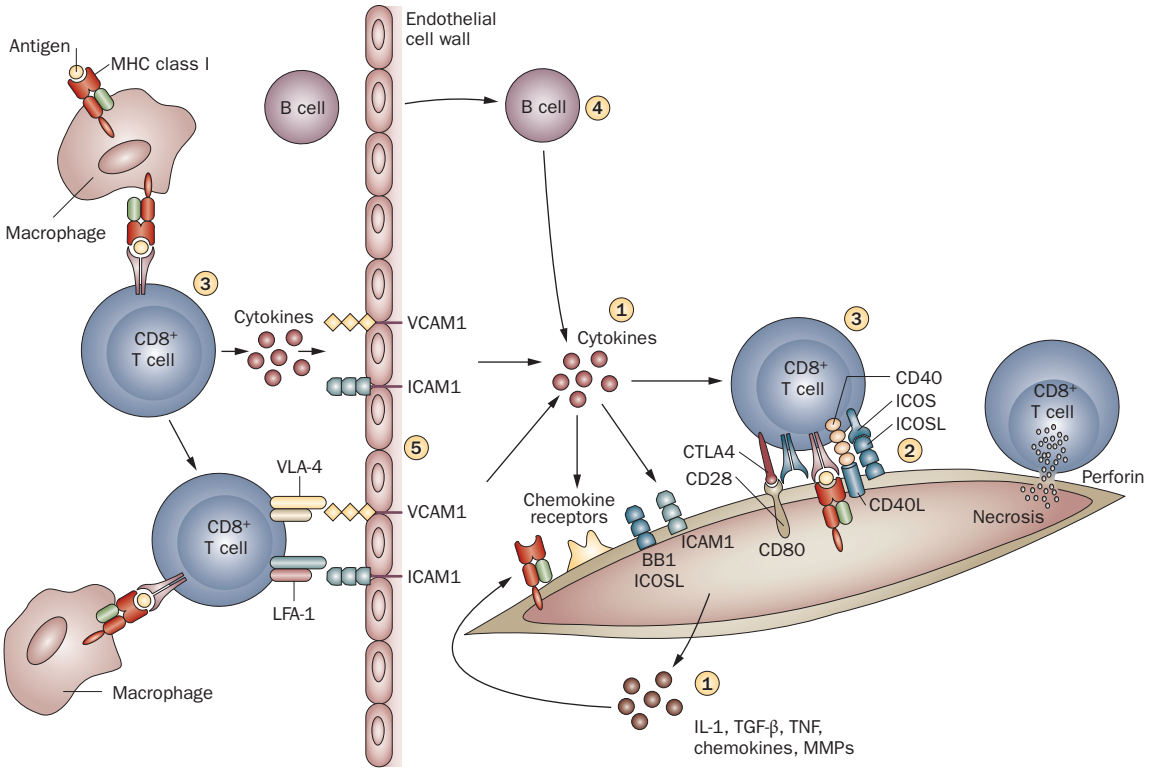

Figure 1 | Therapeutic targets in the immunopathogenesis of myositis. The main immune players involved in the pathomechanism of myositis are depicted, including T-cell and B-cell activation molecules in circulation, molecules that control transmigration across the endothelial cell wall, cytokines and chemokines, and molecules associated with the formation of the immunological synapse between activated T cells and the muscle fiber. Novel drugs relevant to the treatment of myositis could include those directed against (1) cytokines and chemokines, (2) molecules in the immune synapse formed between activated T cells and muscle fibers, (3) T cells and their signal transduction molecules, (4) B cells, and (5) molecules involved in transmigration across the endothelial cell wall. Abbreviations: CD40L, CD40 ligand; CTLA4, cytotoxic T-lymphocyte-associated protein 4; ICAM1, intercellular adhesion molecule 1; ICOS, inducible T-cell co-stimulator; ICOSL, inducible T-cell co-stimulator ligand; IL-1, interleukin-1; LFA-1, leukocyte function-associated antigen 1; TGF-β, transforming growth factor β; MMP, metalloproteinase; TNF, tumor necrosis factor; VCAM1, vascular cell adhesion molecule 1; VLA-4, very late activation antigen 4. Permission to adapt figure obtained from Nature Publishing Group © Dalakas, M. C. *Nat. Clin. Pract. Neurol.* **2**, 437–447 (2006).

switched to an alternate-day pattern of administration, with the aim of reducing the daily dose by 5–10 mg every 2–3 weeks, according to efficacy and adverse effects, until the lowest possible dose that controls the disease is reached. In patients with severe disease, treatment might start with intravenous methyl-prednisolone at a dose of 1 g per day for 3–5 days and then switch to the oral prednisone regimen described above. Some physicians prefer to co-administer an additional immunosuppressant agent such as those discussed in the following section from the outset of therapy, although such practice creates uncertainty as to which drug is the most effective. If by the third month after initiating steroid therapy no objective benefit is observed (defined as increased strength and not simply a lower creatine kinase level or patient-reported increase in energy), the patient is probably unresponsive to steroids; in this setting, tapering of the steroid dose should be accelerated while the second-line mode of therapy is started.

Oral steroid-sparing regimens

In a steroid-responsive patient, the goal is to reach the lowest dose of steroids that prevents a breakthrough of the disease, in order to minimize adverse effects. This reduction is accomplished, in most instances, by the addition of a 'steroid-sparing' drug. The preference for selecting such a drug is empirical and not evidence-based. The following drugs, discussed in no particular order, are commonly used as steroid-sparing agents.[21,45,47,48]

Azathioprine is usually administered orally at a low dosage of 1.5–2 mg/kg daily, although doses of up to 3 mg/kg are preferable. If effective, the results are seen after 6–8 months. Elevation of liver enzymes is the main toxic effect observed in patients administered this drug.

Mycophenolate mofetil is administered orally at a dose of up to 3 g per day, but it can take up to 2–3 months to see the benefits of treatment. Despite being more expensive than other available immunosuppressant drugs, mycophenolate mofetil is preferred by some over other steroid-sparing agents because it is well-tolerated. Gastrointestinal symptoms and leukopenia are the most common adverse effects.

Methotrexate is administered orally up to a total dose of 25 mg weekly, and can also be administered subcutaneously. Methotrexate acts faster than azathioprine with results expected within 6–8 weeks. The most common

© 2010 Macmillan Publishers Limited. All rights reserved

adverse effect of methotrexate use is liver and bone-marrow toxicity.

Ciclosporin is administered at a dose of up to 150 mg twice a day and necessitates monitoring during the first few months to ensure the trough serum level is optimum (100–200 ng/ml). The effects of ciclosporin are seen sooner than those of azathioprine, but the former is more toxic to the kidneys, liver and bone marrow.

Inadequate response to steroids

If treatment with corticosteroids fails to induce remission of disease, or in cases of rapidly progressive disease with severe weakness, steroid-sparing immunosuppressive agents alone are inadequate to increase muscle strength. In these circumstances, intravenous immunoglobulin (IVIg) is the preferred agent of choice, especially for cases of dermatomyositis as the efficacy of this treatment has been demonstrated in a double-blind, placebo-controlled study.[49] The recommended starting dose of IVIg is 2 g/kg. The improvement in strength can be impressive and becomes noticeable even as soon as 15 days after the first infusion. Repeated infusions every 5–8 weeks might be required to maintain the response. In children or patients with diabetes, IVIg can be used soon after the initiation of steroid therapy. In several open-label trials IVIg was also shown to be effective for a majority of patients with polymyositis.[50,51] IVIg has multiple mechanisms of actions relevant to the pathology of polymyositis and dermatomyositis, including the inhibition of cytokines and complement activation, interference with Fc-receptor-binding and blockade of sialic-acid-specific receptors on regulatory macrophages,[52] and interference with immunoregulatory and adhesion molecules.

Inadequate response to steroids and IVIg

In most cases of myositis that fail to respond to therapy with steroids and IVIg, it is prudent to have a critical look at the diagnosis and re-evaluate the patient's history, clinical features and objective response to previous therapies. A new diagnostic muscle biopsy is often necessary. If the diagnosis is reconfirmed, a number of agents can be empirically used.

Rituximab is a monoclonal antibody against $CD20^+$ B cells that results in B-cell depletion for at least 6 months.[53] On the basis of a number of case reports, rituximab at 375 mg/m^2 weekly for 4 weeks, or at 1 g in each of two biweekly infusions (total of 2 g) can be effective for some patients with dermatomyositis and polymyositis who are resistant to other therapies.[54–56] A multicenter, placebo-controlled trial of rituximab in patients with polymyositis and dermatomyositis is underway. Rituximab is generally well-tolerated. Infusion reactions can occur but they are easily controlled with antihistamines or steroids. Infections are extremely rare but physicians should be aware of such possibilities.

Cyclophosphamide is an alkylating agent that inhibits lymphopoietic cells without affecting hematopoietic cells. In addition to T cells, it inhibits cyclical production of antibody-producing B lymphocytes and might be useful in the treatment of myositis where both T and B cells are involved. In patients with interstitial lung disease and severe myositis, this drug can be used at an intravenous dose of 0.8–1 g/m^2 monthly. An oral regimen of 1.5–2 mg/kg daily might be preferred by some. The benefit of this treatment can vary but is generally not substantial. The drug can be toxic to the urinary bladder, bone marrow and liver.

Tacrolimus binds to the immunophilin FKBP12 and inhibits calcineurin, resulting in inhibition of T-cell signal transduction and IL-2 transcription, both of which are relevant to the pathogenesis of myositis. This drug can be effective in some difficult-to-treat cases of polymyositis, especially in patients with interstitial lung disease.[57–59] The risks of tacrolimus therapy are similar to, but usually more severe than, those of ciclosporin therapy.

Step-by-step approach to therapy

Figure 2 suggests a practical algorithm for a step-by-step approach to the treatment of the various subtypes of myositis. As evidence from clinical trials of various therapies for myositis is scarce, the approach is based largely on empirical evidence. This approach highlights several important issues that should be considered in treatment decision-making, including the need for objective outcome measures, the potential impact of adverse effects of various therapies and the influence of diagnosis of myositis subtype on therapy. Box 2 lists general practical therapeutic considerations in the therapy of myositis.

Future therapeutic prospects

Advances in biotechnology have promoted new products for immunotherapy in the form of monoclonal antibodies or fusion proteins that manipulate the immune system by selectively inhibiting or depleting B cells or T cells, their growth factors, transduction molecules, cytokines, and co-stimulatory or adhesion molecules. All of these factors are involved in the immunopathogenesis of myositis, as depicted in Figure 1 and discussed in detail elsewhere.[45,60,61] The agents discussed in this section could be considered in future studies of myositis therapy.

Anecdotal reports suggest that TNF inhibitors (such as infliximab, adalimubab and etanercept) can be helpful in the treatment of some patients with dermatomyositis and polymyositis, although other reports show no such benefit or induction of flares during such treatment; in addition, onset of myositis has been reported in patients with rheumatoid arthritis during anti-TNF therapy.[62–65]

Drugs that target co-stimulation molecules such as the human lymphocyte membrane proteins LFA-1 and LFA-3 have been approved for the treatment of psoriasis. These drugs, which include efalizumab and alefacept, could be of interest in myositis, provided that safety concerns regarding the occurrence of progressive multifocal leukoencephalopathy are resolved.[66]

Daclizumab is an IL-2 receptor antagonist that targets the signaling pathways involved in T-cell activation. Phase III clinical trials are underway for multiple sclerosis, in which the drug has shown excellent tolerance and promising efficacy.[67] Daclizumab could be useful to explore in the treatment of myositis.

© 2010 Macmillan Publishers Limited. All rights reserved

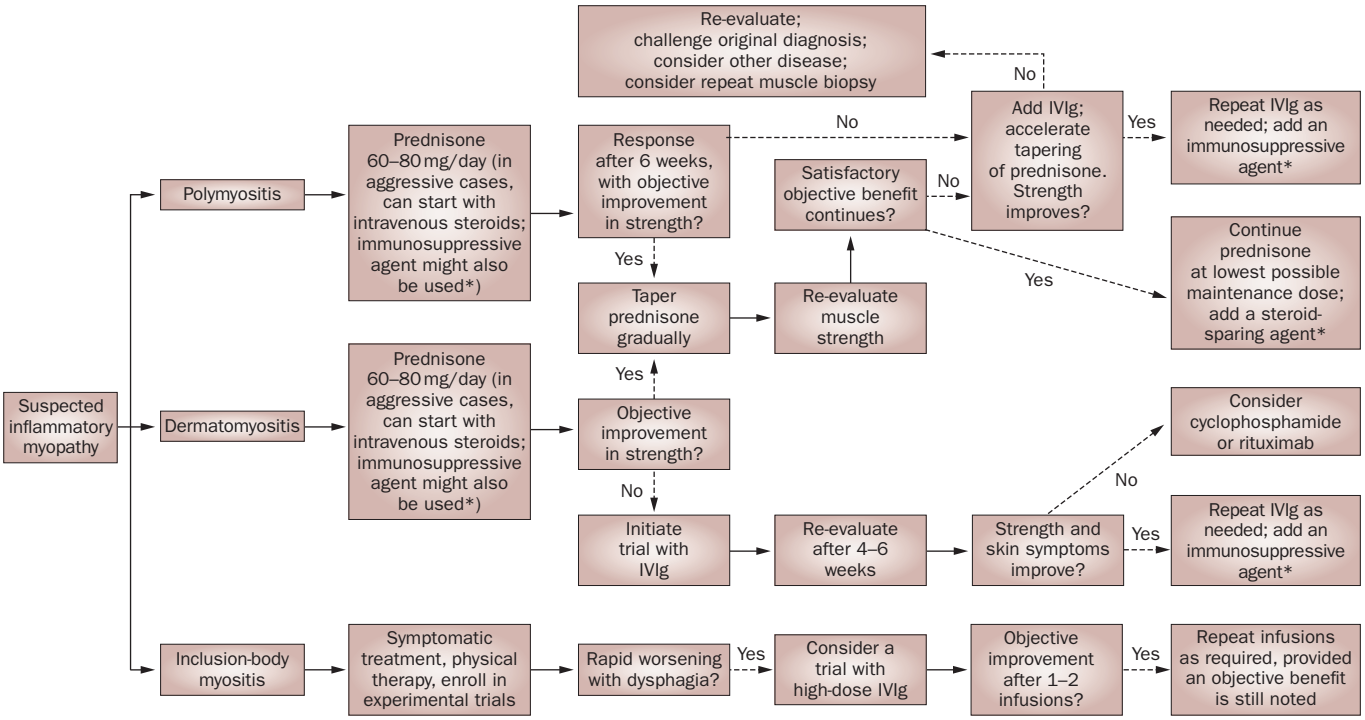

Figure 2 | Algorithm of a suggested step-by-step approach to the treatment of myositis by subtype. *Methotrexate, azathioprine or mycophenolate mofetil. Abbreviation: IVIg, intravenous immunoglobulin.

Anti-T-cell-signaling drugs such as alemtuzumab might also be useful in myositis. Alemtuzumab is promising in multiple sclerosis, has been shown to be effective in one case of polymyositis[68] and has been explored in IBM, as discussed below.

Fingolimod, an anti-T-cell-migration agent, traps lymphocytes in the lymphoid organs. This drug has shown an excellent safety and efficacy profile in phase III trials of multiple sclerosis.[69]

Eculizumab is a monoclonal antibody against the complement protein C5 that could be relevant to the treatment of dermatomyositis, of which the main cause is a complement-mediated microvasculopathy.[23,53,70]

Regarding anti-B-cell agents, in addition to rituximab, agents that target B-cell growth factors, such as BAFF and APRIL, could have promise for the treatment of myositis,[53] and might be explored in this setting.

Anti-adhesion-molecule drugs affect transmigration of B cells or T cells across the endothelial cell wall. Natalizumab, the best-known agent in this category, is already on the market for multiple sclerosis and could be an appropriate drug to test in myositis.

Although these agents are generally well-tolerated, safety concerns—especially reactivation of latent JC virus or other viruses or induction of tumors—should be considered when long-term therapy with monoclonal antibodies is entertained.

Treatment of IBM

Reconciling inflammation and degeneration

IBM is a complex disorder. In addition to T-cell-mediated cytotoxicity identical to that observed in polymyositis, the disease has degenerative features consisting of vacuoles and accumulation of amyloid-related proteins, most prominently in muscle fibers not invaded by T cells. This observation suggests that two processes act independently or in concert with each other in IBM: a primary immune process and a degenerative one.[14] The scenario that the disease begins with the accumulation of misfolded proteins, which then act as neoantigens to trigger a cytotoxic lymphocytic attack on muscle fiber, remains untested. Regardless of whether the primary event is inflammatory or whether it involves protein dysregulation, evidence suggests interplay between the two processes in the pathogenesis of IBM. Proinflammatory cytokines have been shown not only to correlate with the endomysial accumulation of amyloid, phosphorylated tau, ubiquitin and αβ-crystallin, but also to induce tau phosphorylation and the accumulation of amyloid aggregates.[43,71] Cytokines also stimulate myofibers to produce inflammatory mediators in an autoamplificatory mechanism, which further enhances the chronicity of inflammation, amyloid formation and cell stress in IBM.

Experience with conventional immunotherapies

Although a number of patients with IBM might show a transient response to steroid therapy, the majority do not. Methotrexate, ciclosporin, azathioprine or mycophenolate mofetil are largely ineffective, although some patients might initially respond to some degree.[8,9,14,47,72] IVIg can provide some benefit to a small proportion of patients for a short period of time, especially for those with dysphagia,[73–75] but its overall effect is disappointing.

The resistance of IBM to these therapies has raised concerns that the degenerative process, rather than the

© 2010 Macmillan Publishers Limited. All rights reserved

inflammatory one, might be more relevant. A lack of agents that target degeneration, however, has prompted the suggestion that strategies that aggressively suppress inflammation by targeting T cells and molecules implicated in their activation via MHC could also suppress muscle degeneration, through their effects on cell-stress and protein misfolding.[43,71] Based on the interaction of inflammation and degeneration noted above, the concept of 'neuroinflammation', using IBM as a model, was introduced. Accordingly, the use of potent anti-inflammatory agents as a means of suppressing the accumulation of potentially toxic or stressor molecules within the muscle fibers warrants investigation.[71]

With this aim in mind, a small, uncontrolled, proof-of-principle trial with alemtuzumab, a humanized monoclonal antibody that causes long-lasting depletion of peripheral blood lymphocytes (PBLs), was performed to examine whether the drug reduces numbers of endomysial T cells and alters the natural course of IBM.[76] In the study, 13 patients with established sporadic IBM received 0.3 mg/kg per day alemtuzumab for 4 days. Six months after therapy, the overall decline in muscle strength was only 1.9%, compared with the 14.9% decline seen during the 12 months that preceded the start of therapy. Apart from this short-term stabilization of the disease, no substantial improvement was seen in strength, as only four patients reported improvements of 4–19%. Subjectively, however, 6 of the 13 patients reported improved performance of daily activities. Repeated muscle biopsies showed a mean reduction in PBLs of 50% ($P<0.008$), and reduced messenger RNA expression of stressor molecules including Fas, Mip-1a and αβ-crystallin; by contrast, messenger RNA levels of desmin, a regeneration-associated molecule, were increased. These observations are both discouraging and encouraging. The discouraging news is that, in spite of an observed reduction in T cells and in some stressor molecules in the muscle, the patients' muscle strength did not significantly improve, which suggests that the disease is more complex than previously thought. The encouraging news is that the reduction of these molecules was associated with short-term disease stability, which suggests that long-term therapy with potent anti-T-cell agents, if they are proved safe for long-term use, could produce clinically meaningful changes. Ideally, agents that affect both degeneration and inflammation might be better suited to the treatment of IBM than agents that target either alone.

Symptomatic therapy

For life-threatening dysphagia, which is a feature of late-stage disease in some patients with IBM, IVIg therapy can be considered on the basis of the results of a single placebo-controlled study and other, small open-label trials;[73,75] cricopharyngeal myotomy might be another option for this symptom.[77] A nonfatiguing, resistance-exercise program has also been shown to be of some benefit to patients with IBM.[78] Occupational and rehabilitation therapies can be useful by offering devices to improve ambulation and provide assistance on how best to walk without falling, that is, by 'locking' of the knees or by use of light braces.

Box 2 | Practical therapeutic considerations

- Most patients with a confirmed diagnosis of polymyositis or dermatomyositis seem to respond to treatment with prednisone at least to some degree
- A patient with presumed polymyositis who does not show a response to any form of immunotherapy probably has inclusion-body myositis or an inflammatory dystrophy; consideration of the other disease and repeat of muscle biopsy is recommended
- If prednisone or other immunosuppressive therapies do not improve the patients' muscle strength or become ineffective, they should be discontinued to avoid severe, irreversible adverse effects
- There is no evidence that, in an unresponsive patient, continued therapy with low-dose prednisone or an immunosuppressive agent can prevent further disease progression
- Intravenous immunoglobulin is a viable treatment option as second-line therapy in patients with polymyositis and dermatomyositis; however, this therapy should be discontinued if no objective benefit is observed after 2–3 infusions
- In patients with cancer-associated myositis, the cancer should be treated aggressively; in patients with dermatomyositis the possibility of cancer should be considered for at least the first 3 years after disease onset
- Patients with interstitial lung disease might have high mortality and require more-aggressive treatment; cyclophosphamide, tacrolimus or rituximab might be the most suitable agent in this setting
- Physical therapy should be started early in the disease in order to preserve existing muscle function, avoid disuse atrophy, and prevent joint contractures

Conclusions

The significant progress made in unraveling the immunopathogenesis of myositis, if properly utilized, can help us distinguish polymyositis from common mimics, including inflammatory dystrophies, necrotizing myositis and IBM. Targeting the correct myositis subtype can prevent unnecessary application of potentially toxic immunotherapies. The main concerns with the present treatment of myositis are a lack of controlled clinical trials, the empirical approach to therapy and a lack of functional scales to capture clinically meaningful changes in muscle strength. The availability of new monoclonal antibodies or fusion proteins are promising as targeted treatment options for all forms of myositis and need to be tested in controlled trials. The main dilemma is how best to approach the treatment of IBM, an arguably complex form of myositis. Recent data that indicate an interplay between the endomysially accumulated inflammatory molecules and degenerative or stressor molecules suggest that, in IBM, the process of cell-stress and protein misfolding could be suppressed by use of strategies that target molecules implicated in lymphocyte activation processes.

Review criteria

The PubMed database was searched for original articles and reviews on myositis using the search terms "myositis" and "treatment", alone and in combination. The search was limited to articles published in English-language journals. Articles from the author's own collection were also included. The abstracts were retrieved and prioritized by content and full articles were obtained as appropriate.

© 2010 Macmillan Publishers Limited. All rights reserved

1. Dalakas, M. C. Polymyositis, dermatomyositis and inclusion-body myositis. *N. Engl. J. Med.* **325**, 1487–1498 (1991).
2. Engel, A. G. & Hohlfeld, R. in *Myology* 3rd edn (eds Engel, A. G. & Franzini-Armstrong, C.) 1321–1366 (McGraw-Hill, New York, 2004).
3. Mastaglia, F. L. & Phillips, B. A. Idiopathic inflammatory myopathies: epidemiology, classification and diagnostic criteria. *Rheum. Dis. Clin. North Am.* **28**, 723–741 (2002).
4. Dalakas, M. C. & Hohlfeld, R. Polymyositis and dermatomyositis. *Lancet* **362**, 971–982 (2003).
5. Dalakas, M. C. Inflammatory disorders of muscle: progress in polymyositis, dermatomyositis and inclusion body myositis. *Curr. Opin. Neurol.* **17**, 561–567 (2004).
6. Antiochos, B. B. *et al.* Malignancy is associated with dermatomyositis but not polymyositis in Northern New England, USA. *J. Rheumatol.* **36**, 2704–2710 (2009).
7. Sekul, E. A. & Dalakas, M. C. Inclusion body myositis: new concepts. *Semin. Neurol.* **13**, 256–263 (1993).
8. Needham, M. & Mastaglia, F. L. Inclusion body myositis: current pathogenetic concepts and diagnostic and therapeutic approaches. *Lancet Neurol.* **6**, 620–631 (2007).
9. Needham, M. & Mastaglia, F. L. Sporadic inclusion body myositis: a continuing puzzle. *Neuromuscul. Disord.* **18**, 6–16 (2008).
10. Griggs, R. C. *et al.* Inclusion body myositis and myopathies. *Ann. Neurol.* **38**, 705–713 (1995).
11. Greenberg, S. A. *et al.* Interferon-α/β-mediated innate immune mechanisms in dermatomyositis. *Ann. Neurol.* **57**, 664–678 (2005).
12. Askanas, V. & Engel, W. K. Sporadic inclusion-body myositis and hereditary inclusion-body myopathies: current concepts of diagnosis and pathogenesis. *Curr. Opin. Rheumatol.* **10**, 530–542 (1998).
13. Mendel, J. R., Sahenk, Z., Gales, L. & Paul, L. Amyloid filaments in inclusion body myositis. Novel findings provide insight into nature of filaments. *Arch. Neurol.* **48**, 1229–1234 (1991).
14. Dalakas, M. C. Sporadic inclusion body myositis: diagnosis, pathogenesis and therapeutic strategies. *Nat. Clin. Prac. Neurol.* **2**, 437–447 (2006).
15. Dalakas, M. C. Toxic and drug-induced myopathies. *J. Neurol. Neurosurg. Psych.* **80**, 832–838 (2009).
16. Karpati, G. & Carpenter, S. Pathology of the inflammatory myopathies. *Baillière's Clin. Neurol.* **2**, 527–556 (1993).
17. Emslie-Smith, A. M., Arahata, K. & Engel, A. G. Major histocompatibility complex class I antigen expression, immunologicalization of interferon subtypes, and T cell-mediated cytotoxicity in myopathies. *Hum. Pathol.* **20**, 224–231 (1989).
18. Karpati, G., Pouliot, Y. & Carpenter, S. Expression of immunoreactive major histocompatability complex products in human skeletal muscles. *Ann. Neurol.* **23**, 64–72 (1988).
19. Chahin, N. & Engel, A. G. Correlation of muscle biopsy, clinical course, and outcome in PM and sporadic IBM. *Neurology* **70**, 418–424 (2008).
20. Blume, G., Pestronk, A., Frank, B. & Johns, D. R. Polymyositis with cytochrome oxidase negative muscle fibres. Early quadriceps weakness and poor response to immunosuppressive therapy. *Brain* **120**, 39–45 (1997).
21. Dalakas, M. C. Therapeutic approaches in patients with inflammatory myopathies. *Semin. Neurol.* **23**, 199–206 (2003).
22. Miller, F. W. *et al.* Controlled trial of plasma exchange and leukopheresis in patients with polymyositis and dermatomyositis. *N. Engl. J. Med.* **326**, 1380–1384 (1992).
23. Kissel, J. T., Mendell, J. R. & Rammohan, K. W. Microvascular deposition of complement membrane attack complex in dermatomyositis. *N. Engl. J. Med.* **314**, 329–334 (1986).
24. Emslie-Smith, A. M. & Engel, A. G. Microvascular changes in early and advanced dermatomyositis: a quantitative study. *Ann. Neurol.* **27**, 343–356 (1990).
25. Dalakas, M. C. Immunopathogenesis of inflammatory myopathies. *Ann. Neurol.* **37** (Suppl. 1), S74–S86 (1995).
26. López de Padilla, C. M. *et al.* Plasmacytoid dendritic cells in inflamed muscles of patients with juvenile dermatomyositis. *Arthritis Rheum.* **56**, 1658–1668 (2007).
27. Tews, D. S. & Goebel, H. H. Expression of cell adhesion molecules in inflammatory myopathies. *J. Neuroimmunol.* **59**, 185–194 (1995).
28. De Bleecker, J. L. & Engel, A. G. Expression of cell adhesion molecules in inflammatory myopathies and Duchenne dystrophy. *J. Neuropathol. Exp. Neurol.* **53**, 369–376 (1994).
29. De Bleecker, J. L., De Paepe, B., Vanwalleghem, I. E. & Schröder, J. M. Differential expression of chemokines in inflammatory myopathies. *Neurology* **58**, 1779–1785 (2002).
30. Civatte, M. *et al.* Expression of the beta chemokines CCL3, CCL4, CCL5 and their receptors in idiopathic inflammatory myopathies. *Neuropathol. Appl. Neurobiol.* **31**, 70–79 (2005).
31. Illa, I. *et al.* Signal transducer and activator of transcription 1 in human muscle: implications in inflammatory myopathies. *Am. J. Pathol.* **151**, 81–88 (1997).
32. Dalakas, M. C. Mechanisms of disease: signaling pathways and immunobiology of inflammatory myopathies. *Nat. Clin. Pract. Rheumatol.* **2**, 219–227 (2006).
33. Arahata, K. & Engel, A. G. Monoclonal antibody analysis of mononuclear cells in myopathies. I: Quantitation of subsets according to diagnosis and sites of accumulation and demonstration and counts of muscle fibers invaded by T cells. *Ann. Neurol.* **16**, 193–208 (1984).
34. Arahata, K. & Engel, A. G. Monoclonal antibody analysis of mononuclear cells in myopathies III Immunoelectron microscopy aspects of cell-mediated muscle fibre injury. *Ann. Neurol.* **19**, 112–125 (1986).
35. Goebel, N. *et al.* Differential expression of perforin in muscle-infiltrating T cells in polymyositis and dermatomyositis. *J. Clin. Invest.* **97**, 2905–2910 (1996).
36. Bender, A. *et al.* T cell receptor repertoire in polymyositis: clonal expansion of autoaggressive $CD8^+$ T cells. *J. Exp. Med.* **181**, 1863–1868 (1995).
37. Engel, A. G. & Arahata, K. Mononuclear cells in myopathies: quantitation of functionally distinct subsets, recognition of antigen-specific cell-mediated cytotoxicity in some diseases, and implications for the pathogenesis of the different inflammatory myopathies. *Hum. Pathol.* **17**, 704–721 (1986).
38. Amemiya, K., Granger, R. P. & Dalakas, M. C. Clonal restriction of T-cell receptor expression by infiltrating lymphocytes in inclusion body myositis persists over time. Studies in repeated muscle biopsies. *Brain* **123**, 2030–2039 (2000).
39. Hofbauer, M. *et al.* Clonal tracking of autoaggressive T cells in polymyositis by combining laser microdissection, single-cell PCR, and CDR3-spectratype analysis. *Proc. Natl Acad. Sci. USA* **100**, 4090–4095 (2003).
40. Wiendl, H. *et al.* Muscle fibres and cultured muscle cells express the B7.1/2-related inducible co-stimulatory molecule, ICOSL: implications for the pathogenesis of inflammatory myopathies. *Brain* **126**, 1026–1035 (2003).
41. Wiendl, H., Hohlfeld, R. & Kieseier, B. C. Immunobiology of muscle: advances in understanding an immunological microenvironment. *Trends Immunol.* **26**, 373–380 (2005).
42. Schmidt, J., Rakocevic, G., Raju, R. & Dalakas, M. C. Upregulated inducible co-stimulator (ICOS) and ICOS-ligand in inclusion body myositis muscle: significance for $CD8^+$ T cell cytotoxicity. *Brain* **127**, 1182–1190 (2004).
43. Schmidt, J. *et al.* Interrelation of inflammation and APP in sIBM: IL-1β induces accumulation of β-amyloid in skeletal muscle. *Brain* **131**, 1228–1240 (2008).
44. Targoff, I. N. Autoantibodies and their significance in myositis. *Curr. Rheumatol. Rep.* **10**, 333–340 (2008).
45. Dalakas, M. C. Therapeutic targets in patients with inflammatory myopathies: present approaches and a look to the future. *Neuromuscul. Disord.* **16**, 223–236 (2006).
46. Bunch, T. W. Prednisone and azathioprine for polymyositis: long-term followup. *Arthritis Rheum.* **24**, 45–48 (1981).
47. Mastaglia, F. L., Phillips, B. A. & Zilko, P. Treatment of inflammatory myopathies. *Muscle Nerve* **20**, 651–664 (1997).
48. Dalakas, M. C. Current treatment of the inflammatory myopathies. *Curr. Opin. Rheumatol.* **6**, 595–601 (1994).
49. Dalakas, M. C. *et al.* A controlled trial of high-dose intravenous immune globulin infusions as treatment for dermatomyositis. *N. Engl. J. Med.* **329**, 1993–2000 (1993).
50. Mastaglia, F. L., Phillips, B. A. & Zilko, P. J. Immunoglobulin therapy in inflammatory myopathies. *J. Neurol. Neurosurg. Psychiatry* **65**, 107–110 (1998).
51. Chérin, P. Current therapy for polymyositis and dermatomyositis [French]. *Rev. Med. Interne.* **29** (Spec. No. 2), 9–14 (2008).
52. Dalakas, M. C. Intravenous immunoglobulin in autoimmune neuromuscular diseases. *JAMA* **291**, 2367–2375 (2004).
53. Dalakas, M. C. B cells as therapeutic targets in autoimmune neurological disorders. *Nat. Clin. Pract. Neurol.* **4**, 557–567 (2008).
54. Levine, T. D. Rituximab in the treatment of dermatomyositis: an open-label pilot study. *Arthritis Rheum.* **52**, 601–607 (2005).
55. Chung, L., Genovese, M. C. & Fiorentino, D. F. A pilot trial of rituximab in the treatment of patients with dermatomyositis. *Arch. Dermatol.* **143**, 763–767 (2007).
56. Kaposztas, Z., Etheridge, W. B. & Kahan, B. D. Case report: successful treatment of posttransplant lymphoproliferative disorder and quiescence of dermatomyositis with rituximab and sirolimus. *Transplant. Proc.* **40**, 1744–1746 (2008).
57. Oddis, C. V., Sciurba, F. C., Elmagd, K. A. & Starzl, T. E. Tacrolimus in refractory polymyositis with interstitial lung disease. *Lancet* **353**, 1762–1763 (1999).
58. Shimojima, Y. *et al.* Efficacy of tacrolimus in treatment of polymyositis associated with myasthenia gravis. *Clin. Rheumatol.* **23**, 262–265 (2004).
59. Yamada, A., Ohshima, Y., Omata, N., Yasutomi, M. & Mayumi, M. Steroid-sparing effect of tacrolimus in a patient with juvenile dermatomyositis presenting poor bioavailability of cyclosporine A. *Eur. J. Pediatr.* **163**, 561–562 (2004).
60. Hohlfeld, R. & Dalakas, M. C. Basic principles of immunotherapy for neurologic diseases. *Semin. Neurol.* **23**, 121–132 (2003).
61. Wiendl, H. Idiopathic inflammatory myopathies: current and future therapeutic options. *Neurotherapeutics* **5**, 548–557 (2008).

© 2010 Macmillan Publishers Limited. All rights reserved

62. Hengstman, G. J. *et al.* Successful treatment of dermatomyositis and polymyositis with anti-tumor necrosis-factor-alpha: preliminary observations. *Eur. Neurol.* **50**, 10–15 (2003).
63. Labioche, I. *et al.* Refractory polymyositis responding to infliximab: extended follow-up. *Rheumatology (Oxford)* **43**, 531–532 (2004).
64. Hengstman, G. J., van den Hoogen, F. H. & van Engelen, B. G. Treatment of dermatomyositis and polymyositis with anti-tumor necrosis factor-alpha: long-term follow-up. *Eur. Neurol.* **52**, 61–63 (2004).
65. Dastmalchi, M. *et al.* A high incidence of disease flares in an open pilot study of infliximab in patients with refractory polymyositis. *Ann. Rheum. Dis.* **67**, 1670–1677 (2008).
66. US Food and Drug Administration. *FDA public health advisory: updated safety information about Raptiva (efalizumab)* [http://www.fda.gov/Drugs/DrugSafety/PublicHealthAdvisories/ucm110605.htm] (2009).
67. Rose, J. W. *et al.* Daclizumab phase II trial in relapsing and remitting multiple sclerosis: MRI and clinical results. *Neurology* **69**, 785–789 (2007).
68. Thomson, B. *et al.* Alemtuzumab (Campath-1H) for treatment of refractory polymyositis. *J. Rheumatol.* **35**, 2080–2082 (2008).
69. O'Connor, P. *et al.* Oral fingolimod (FTY720) in multiple sclerosis: two-year results of a phase II extension study. *Neurology* **72**, 73–79 (2009).
70. Basta, M. & Dalakas, M. C. High-dose intravenous immunoglobulin exerts its beneficial effect in patients with dermatomyositis by blocking endomysial deposition of activated complement fragments. *J. Clin. Invest.* **94**, 1729–1735 (1994).
71. Dalakas, M. C. Interplay between inflammation and degeneration: using inclusion body myositis to study "neuroinflammation". *Ann. Neurol.* **64**, 1–3 (2008).
72. Mowzoon, N., Sussman, A. & Bradley, W. G. Mycophenolate (CellCept) treatment of myasthenia gravis, chronic inflammatory polyneuropathy and inclusion body myositis. *J. Neurol. Sci.* **185**, 119–122 (2001).
73. Dalakas, M. C. *et al.* Treatment of inclusion body myositis with IVIg: a double-blind, placebo-control study. *Neurology* **48**, 712–716 (1997).
74. Walter, M. C. *et al.* High-dose immunoglobulin therapy in sporadic inclusion body myositis: a double-blind, placebo-controlled study. *J. Neurol.* **247**, 22–28 (2000).
75. Cherin, P. *et al.* Intravenous immunoglobulin for dysphagia of inclusion body myositis. *Neurology* **58**, 326 (2002).
76. Dalakas, M. C. *et al.* Effect of alemtuzumab (CAMPATH 1-H) in patients with inclusion body myositis. *Brain* **132**, 1536–1544 (2009).
77. Verma, A., Bradley, W., Adesina, A. M., Sofferman, R. & Pendlebury, W. W. Inclusion body myositis with cricopharyngeus muscle involvement and severe dysphagia. *Muscle Nerve* **14**, 470–473 (1991).
78. Spector, S. A. *et al.* Safety and efficacy of strength training in patients with sporadic inclusion body myositis. *Muscle Nerve* **20**, 1242–1248 (1997).

Acknowledgments

Charles P. Vega, University of Irvine, CA, is the author of and is solely responsible for the content of the learning objectives, questions and answers of the MedscapeCME-accredited continuing medical education activity associated with this article.

© 2010 Macmillan Publishers Limited. All rights reserved